



DATE PRESENTING CLINICAL SIGNS

10.31.25 History: Grade 2/6 systolic murmur on left side first noted Aug of 2025. Asymptomatic. Diabetic; well managed. History of vacuolar hepatopathy and atopic allergies. Asses prior to dental.

PATIENT

Lilly Dimarzo -Current medications: Clindamycin 37.5mg BID for 7 days started Oct 14th- refilling today until dental Vetsulin 3 U BID for 1 + years.
-Sedation used: Not required to complete full diagnostic ultrasound.
-Pertinent previous ultrasound results: No previous.
-STAT: Not requested.

SPECIES

Canine

BREED

Chihuahua

SEX

FS

AGE

6.6.13

WEIGHT

11.2lbs

INTERPRETED BY

Maggie Machen Lamy, DVM, DACVIM (Cardiology)

HOSPITAL NAME

Greenbrier VC

REFERRING VET

Dr. Boccanfuso

INVOICE

45601

ECHOCARDIOGRAM FINDINGS

2D, m-mode, color flow and doppler imaging is available. Mild diffuse thickening of mitral valve leaflets with no prolapse into the left atrial lumen. Trace/mild eccentric mitral regurgitation with no left atrial dilation (LA:Ao <1.4). Elevated MR velocity. Normal LV diameter with adequate myocardial function. The tricuspid valve appears mildly thickened with trace tricuspid regurgitation. Normal velocity. Normal right atrial and ventricular diameter and morphology indicating no overt evidence of pulmonary arterial hypertension. The pulmonic and aortic valves are normal in morphology and mobility. Normal pulmonic and aortic outflow velocities with laminar flow. No obvious aortic and trace pulmonic insufficiency. No pericardial or pleural effusion noted. No obvious cardiac masses.

CARDIAC CHART

CANINE CARDIAC PARAMETERS	MR VMAX (m/s)	TR VMAX (m/s)	LA/AO (Boon method)	LA/AO (Heart Base; Swe)	FS (%)	EF (%)	EPSS (cm)
NORMAL PARAMETER	4.5-5.5	<2.7	1.3	<1.6	28-40	40-100	<0.6
PATIENT	6.8	2.7	NM	1.3	32	62	NM
CANINE CARDIAC PARAMETERS	HR (BPM)	AV VMAX (m/s)	PV MAX (m/s)	BODY WEIGHT (kg)	LA 2D short axis Base view (cm)	LVIDd Avg; 2D and m-mode short axis (cm)	LVIDs Avg; 2D and m-mode short axis (cm)
NORMAL PARAMETER	50-100	0.7-1.7	0.7-1.6	BELOW	BELOW	BELOW	BELOW
PATIENT	50	1.7	1.1	5.1	1.5	2.5	1.7
*Normal chamber parameters expressed as a mean value (SD)				3	1.27 (5.3)	2.46 (2.46)	1.36 (5.5)
BODY WEIGHT DEPENDENT PARAMETERS				5	1.40 (4.5)	2.74 (5.2)	1.60 (4.7)
*Note: All measurements based upon multi-modal images and methods. An average value is reported.				10	1.50 (3.8)	3.27 (3.5)	2.06 (3.1)
				15	1.83 (2.0)	3.71 (2.4)	2.43 (2.1)
				20	2.02 (1.9)	4.14 (2.2)	2.80 (2.0)
				25	2.18 (2.4)	4.48 (2.9)	3.10 (2.5)
				30	2.33 (3.3)	4.83 (3.9)	3.39 (3.4)
				35	2.48 (4.3)	5.17 (5.0)	3.69 (4.5)
				40	2.62 (5.2)	5.48 (6.1)	3.96 (5.4)
				50	2.88 (7.1)	6.07 (8.3)	4.46 (7.4)

Adapted from June Boon, Veterinary Echocardiography, 1998
Rishniw M and Hollis NE, J Vet Intern Med 2000; 14:429-435
Hansson et al, Vet Rad and Ultrasound 2002
Bonagura et al. Echocardiography: principles of interpretation, Vet Clin North Am 15:1177, 1995

INTERPRETATION OF THE FINDINGS & FURTHER RECOMMENDATIONS

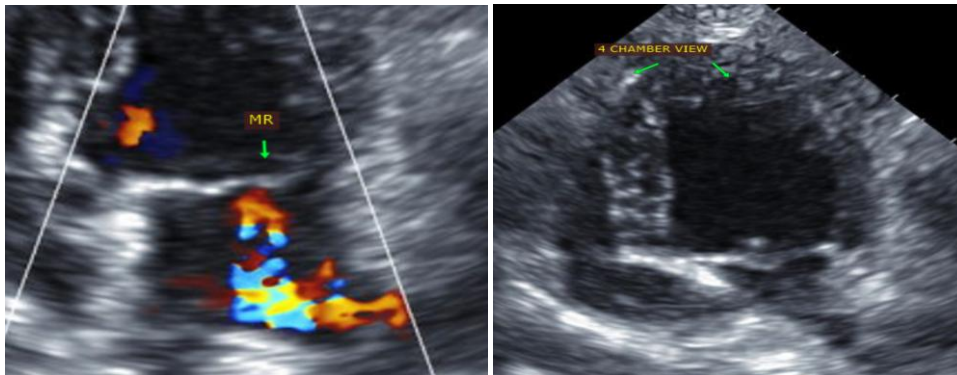
Chronic degenerative valve disease causing trace/mild mitral and tricuspid regurgitation. Lack of significant left atrial enlargement indicates the current risk for complication is low. An elevated MR is noted, and a baseline BP is recommended. No concurrent issues such as systolic dysfunction or pulmonary hypertension are noted in this study.

In a dog with no significant left atrial enlargement, no cardiac medications are clearly indicated. Assessment of progression in the future will help predict long term prognosis, which is highly variable at this stage (B1). Omega fatty acid supplementation and mild salt restriction may be of some long-term benefit. Monitor for development of a cough, labored breathing, exercise intolerance or collapse episodes.

No cardiac contraindication for general anesthesia prior to chamber enlargement.

Recommend conservative monitoring with a recheck echocardiogram in 6-12 months to assess rate of progression, sooner if any development of clinical signs in the interim.

IMAGES



The information and recommendations provided are based on the images presented by the referring veterinarian. No evaluation can be communicated regarding pathology that was not visible in the image/video clips provided.

Thank you for this referral. This report was generated using transcription software, and minor dictation errors may be present. If the clinical or image interpretation does not parallel your findings or if I can be of any further assistance, please contact me.

**Maggie Machen Lamy, DVM
Diplomate of the American College of Veterinary Internal Medicine (Cardiology)
info@sonopath.com**